



Chemical Sterilization of Dogs using Single Bilateral Intra-testicular Injection of Calcium Chloride or Clove Oil

Howaida M. Abu-Ahmed

Department of Surgery, Faculty of Veterinary Medicine, Alexandria University, Egypt

Key words

Dog, chemical sterilization, clove oil, calcium chloride, testosterone

ABSTRACT:

The current study was designed to evaluate the efficacy of single bilateral intra-testicular injection of calcium chloride or clove oil to induce chemical sterilization in ten dogs divided into two groups each of five animals. Chemical sterilization was evaluated by clinical signs, hormonal analysis and histopathological examination. Testosterone level was decreased significantly after injection of both agents with complete degeneration of the interstitial leydig cells and seminiferous tubules while cortisol level was increased during the 1st week after calcium chloride injection. The single bilateral intra-testicular injection of calcium chloride or clove oil proved to be accepted as a suitable alternative to the surgical sterilization of dogs; however clove oil was superior to calcium chloride as it induced less pain and irritation to the dogs.

Corresponding Author: Howaida M. Abu-Ahmed: Howaida_maf@yahoo.com

1. INTRODUCTION

Canine overpopulation and stray dogs represent a worldwide problem, compromising public health and animal welfare (Robertson, 2008). This problem has negative influence on environmental hygiene and zoonosis (Soto et al., 2007). The conventional methods of sterilization is generally not affordable in many developmental countries due to high surgical and postoperative expenses specially for maintaining the animal for long period owing to the delay in surgical wound healing (Baba et al., 2012). In order to minimize post-operative complications and costs associated with conventional surgical castration other in situ noninvasive approaches have been used which include immunocastration and chemical castration and more recently natural oil castration (Dube et al., 1987, Jana and Samanta, 2007 and Abshenas et al., 2013). Chemical orchidectomy with chemical agent has been suggested as a fast and low cost alternative which could be used in a wide range of canine populations, especially in poor regions when problem is more intense (Soto et al., 2007). The single bilateral intra testicular injection of calcium chloride solution resulted in induction of permanent chemosterilization in dogs (Koger, 1978, Samanta, 1998 and Leoci et al., 2014). Abshenas et al., (2013) reported that single bilateral injection of eugenol is effective, economical and permanent method of

sterilization in dogs. The main component of clove oil is eugenol which form about 72-90% of extracted oil, this oil possess various biological properties such as antiviral, anti-oxidant and anti-inflammatory at low concentrations while higher concentration acts as a pro oxidant causing increased generation of tissue damaging free radicals (Jaganathan and Supriyanto, 2012). It has been found that eugenol is cytotoxic to rat hepatocytes (Thompson et al., 1990) and oral mucosal fibroblasts in vitro and cause injury to oral mucosal membrane (Ho et al., 2006). The current study was aimed to evaluate the efficacy of calcium chloride or clove oil to induce chemical sterilization in dogs.

2. MATERIALS AND METHODS

2.1- Dogs:

Ten apparently healthy adult male stray dogs aging (2-3 years) and weighing (15-20 kg) were used in the present study which approved by Institutional Animal Use and Care Committee of Faculty of Veterinary Medicine, Alexandria University. The animals were physically controlled in a dorsal recumbent position after sedation by xylazine HCl injected intramuscular in a dose rate of 1 mg/ kg body weight.

2.2- Experimental protocol:

The dogs were divided into two groups each of five animals, the first group received a single bilateral

intra-testicular injection of 1ml of calcium chloride tincture (Calcium chloride (CaCl_2) dihydrate in pure alcohol 95%) as described by Leoci et al., (2014), While the second group received a single bilateral intra-testicular injection of 1ml clove oil. The intra-testicular injection was performed using a sterile 21 gauge needle directed from caudal to cranial aspect of each testis; the solution was deposited over the entire route by linear infiltration while withdrawing the needle from the proximal to the distal end.

2.3- Clinical evaluation:

The animals were checked for signs of pain and the testicular size was examined every week till the 4th week post injection. Serum samples were collected from both groups before injection and at 2 and 24 hours and at 7days post sterilization for detection of cortisol level and at 2monthes after sterilization for detection of testosterone.

2.4- Histopathological examination:

The testes of both groups were removed by routine castration technique at 60 days after injection for histopathological examination. Tissue specimens were fixed in 10% neutral buffered formalin for at least 24 hours and then embedded in paraffin. The tissue

sections were stained with hematoxylin and eosin and examined by light microscopy.

2.5- Statistical analysis:

The statistical analysis of the obtained data was done by using student's t- test and ANOVA test. The data was expressed as Means \pm SD (SAS, 2006).

3. RESULTS

3.1-Clinical Evaluation:

The two testes became tender and signs of discomfort appeared on the animals 5 minutes post injection in both groups. Testicular swelling was evident in CaCl_2 group; this swelling reached its peak at 72 hrs. then gradually decreased till third week post injection. The swelling is not evident in clove oil group except at 24 hrs. after injection. The testes were severely painful and sensitive to touch and the animal walked with abducted hind limbs during 1st week in CaCl_2 group, animal licked the site of injection which resulted in scrotal erosion (Fig., 1). These signs didn't meet with clove oil.

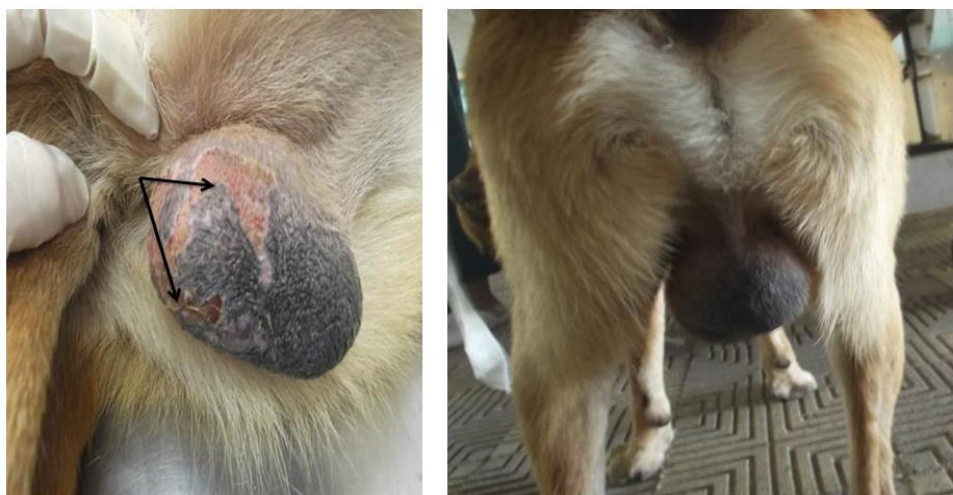


Fig. (1): Showing testicular swelling after CaCl_2 injection. Note: Scrotal erosion in left image (Arrows)

By the end of experiment(at 2monthes), the testes were severely atrophied in CaCl_2 group while in clove oil group the testes didn't show marked decrease in size as in CaCl_2 one. Concerning serum analysis, Testosterone level was significantly decreased in both groups. Cortisol showed significant increase during the first week post calcium chloride injection than clove oil intra-testicular injection (table, 1, 2).

Table (1): Showing the effect of single bilateral intra-testicular injection of $CaCl_2$ and clove oil on serum testosterone level.

Time	CaCl ₂	Clove oil	t- value
Before	8.20±1.22 Ab	8.80±1.80 Aa	4.55*
2 months after	0.28±0.02 Ba 12.33**	0.25±0.02 Ba 12.78**	2.55 NS

-Capital letters indicated that means within the same columns of different litters are significantly different at (P< 0.01).

-Small letters indicated that means within the same row of different litters are significantly different at (P< 0.05).

*= Significant at (P < 0.05)

**= Significant at (P < 0.01).

-NS= Non-significant.

Table (2): Showing the effect of single bilateral intra-testicular injection of $CaCl_2$ and clove oil on serum cortisol level.

Time	CaCl ₂	Clove oil	t- Value
Before	4.80±1.80 Cb	5.00±0.02 BCa	4.55*
2 hrs.	7.90±1.90 Aa	5.30±0.30 Ab	8.55**
24 hrs.	7.70±1.70 Aa	5.10± 0.10ABb	8.60**
7 days	5.80± 1.85 Ba	4.90±0.90 Cb	4.43*

-Capital letters indicated that means within the same columns of different litters are significantly different at (P< 0.01).

-Small letters indicated that means within the same row of different litters are significantly different at (P< 0.05).

*= Significant at (P < 0.05)

**= Significant at (P < 0.01).

3.2-Histopathological examination:

Macroscopic examination of the testes at 60 days post injection revealed that the testes were severely atrophied in 2 animals post $CaCl_2$ injection while only remnants of testicular tissue surrounded by fibrous tissue were observed in other 3 animals. On the other hands no marked decrease in size was observed in clove oil group and no fibrous tissue formation were observed (Fig., 2 a, b).

Intra-testicular injection of both calcium chloride and clove oil induced different degrees of degenerative

changes in testicular tissue including seminiferous tubules, interstitial cells, and Leydig cells. Intra-testicular injection of $CaCl_2$ resulted in replacement of the normal testicular parenchyma with fibrous tissue, complete derangement of the seminiferous tubular architecture with necrosis of the germinal epithelium and replacement of the tubular and interstitial elements with fibrous and hyaline tissues with no evidence for presence of mature or immature germ cells in testicular sections.

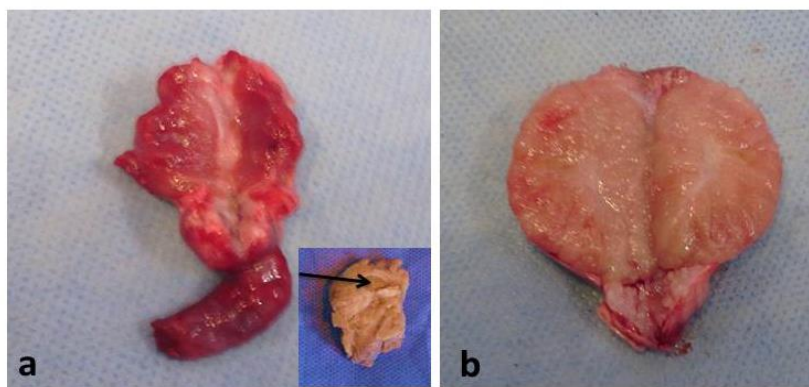


Fig. (2): Showing gross appearance of testis 60 days post injection: a- calcium chloride, b- clove oil. Note testicular remnants surrounded by fibrous tissue (arrow).

Moreover, there was no sign of regeneration in germ cells and interstitial Leydig cells (Fig.3 A, B). While, microscopic examination of testicles from clove oil treated dogs showed atrophy and degeneration of the seminiferous tubules with loss of their normal architectures. Moreover, there were disintegration and washing out of most of their germ cell, irregular and disrupted basal lamina with few necrotic cells desquamated within the tubular lumen (Fig.6 A , B).

Regarding the epididymis, the noticed lesions in both cacl₂ and clove oil treated groups were marked thickening of the epididymal interstitium with fibrous tissue, the epididymal ductules appeared completely devoid of spermatozoa with disarrangement of their architecture and few vacuolation and thinning (cauda) or hypercellularity (caput) in their lining epithelium (Figs. 4, 5, 7, and 8).

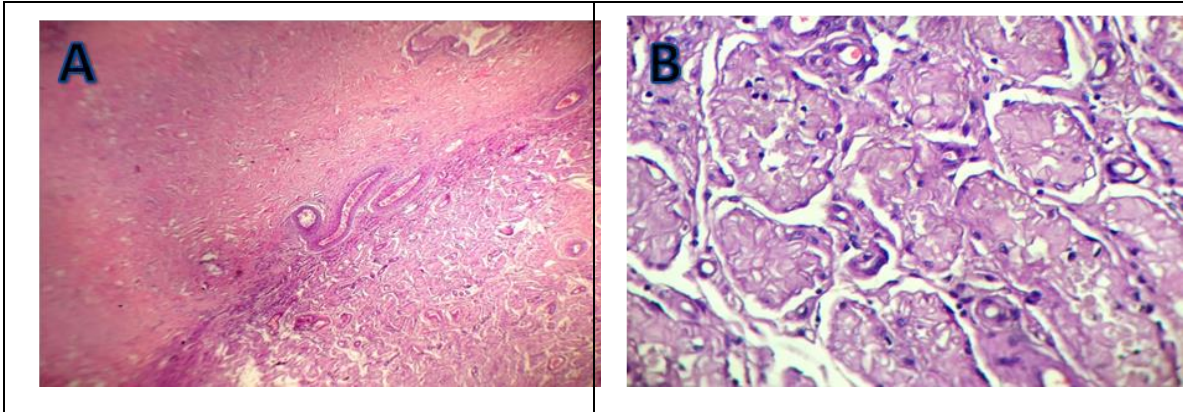


Fig. (3): Representative photomicrograph of a section from testicular remnants 60 days after a single bilateral intra-testicular injection of calcium chloride (H.E) showing: **(A)** replacement of the normal testicular parenchyma with fibrous tissue, X40. **(B)** Complete derangement of the seminiferous tubular architecture with replacement of the tubular and interstitial elements with fibrous and hyaline tissues, X400.

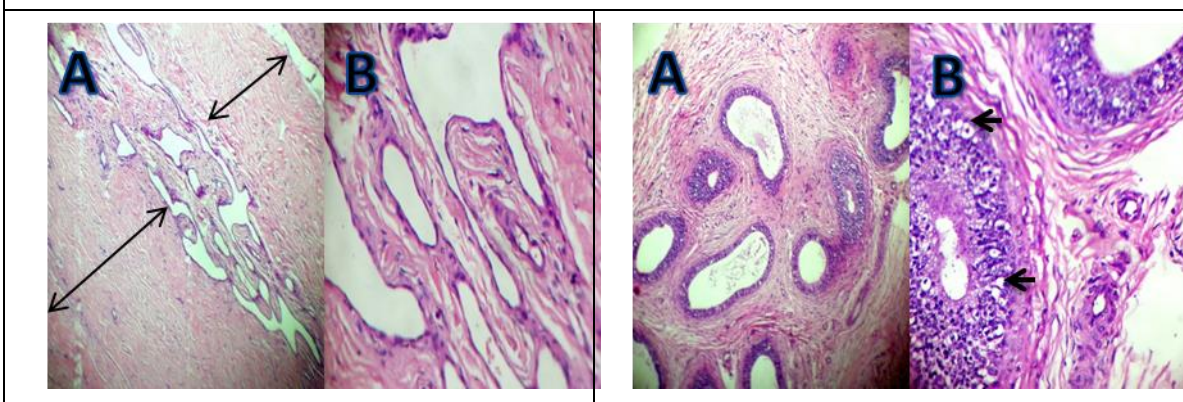


Fig. (4): Representative photomicrograph of a section from cauda epididymis 60 days after a single bilateral intra-testicular injection of calcium chloride (H.E) showing: **(A)** marked thickening of the epididymal interstitium with fibrous tissue, X40. **(B)** The epididymal ductules completely devoid of spermatozoa with complete disarrangement of their architecture, lined with thin attenuated epithelium, X400.

Fig. (5): Representative photomicrograph of a section from caput epididymis 60 days after a single bilateral intra-testicular injection of calcium chloride in a male dog (H.E) showing: **(A)** marked thickening of the epididymal interstitium with fibrous tissue, X100. **(B)**The epididymal ductules completely devoid of spermatozoa with some ductules showing hypercellularity and few vacuolation of their epithelial lining (arrows), X400.

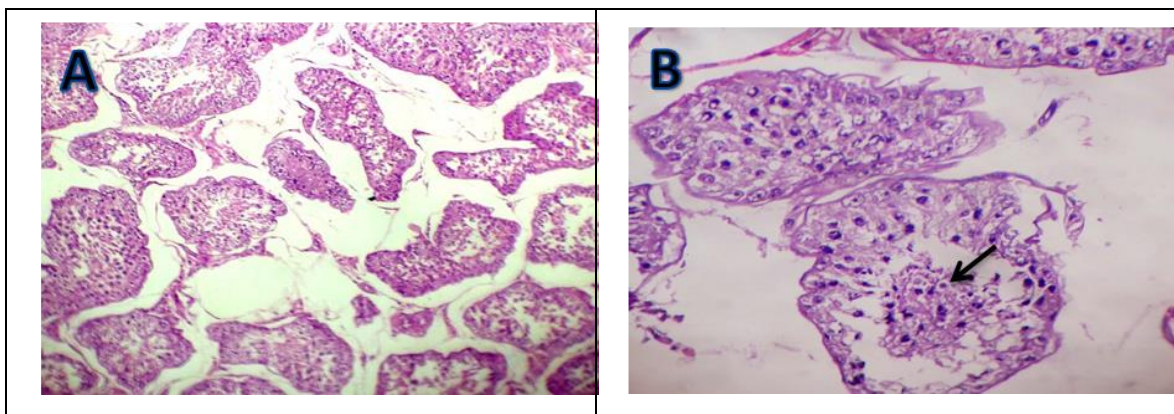


Fig. (6): Representative photomicrograph of a section from testicular remnants 60 days after a single bilateral intra-testicular injection of clove oil (H.E) showing: **(A)** atrophied seminiferous tubules with loss of their normal architectures, X100. **(B)** Degenerated and shrunken tubules with washing out of most of their germ cell, irregular basal lamina and few necrotic spermatogenic cells desquamated within their lumen (arrow), X400.

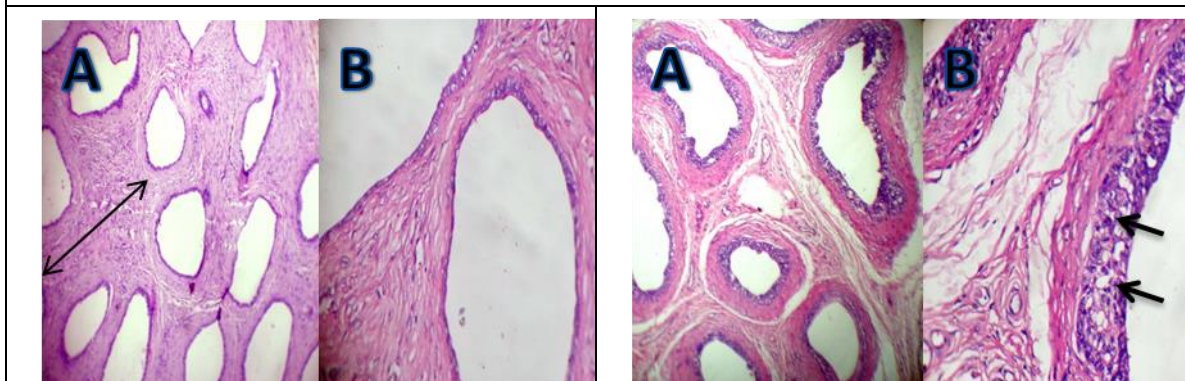


Fig. (7): Representative photomicrograph of a section from cauda epididymis 60 days after a single bilateral intra-testicular injection of clove oil (H.E) showing: **(A)** marked thickening of the epididymal interstitium with fibrous tissue, X40. **(B)** the epididymal ductules completely devoid of spermatozoa, lined with thin attenuated epithelium, X400.

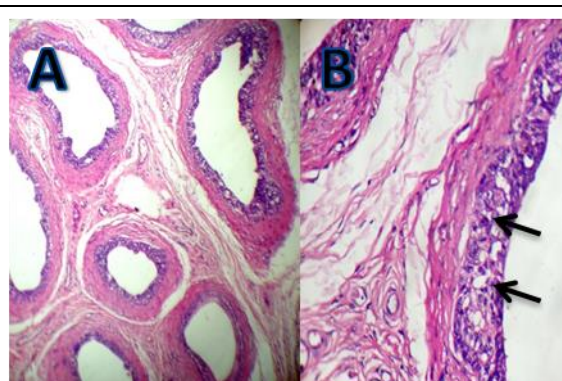


Fig. (8): Representative photomicrograph of a section from caput epididymis 60 days after a single bilateral intra-testicular injection of clove oil (H.E) showing: **(A)** marked thickening of the epididymal interstitium with fibrous tissue, and the epididymal ductules completely devoid of spermatozoa X100. **(B)** Vacuolation of few cells in epithelial lining (arrow), X400.

4.DISCUSSION

Surgical castration is more expensive to be performed in a large scale when a permanent sterilization of dog is desired so there is still need for other effective, simple and inexpensive methods of sterilization. Varieties of chemical sterilant have been developed for injection into testes and/or epididymis of dogs, which were either safe but not effective or vice versa (Oliveira et al., 2007). Ideal chemical sterilizing agent

for domestic animals would be one that effectively arrest spermatogenesis as well as libido and absence of toxic and untoward side effects (Wiebe and Barr, 1984). Chemosterilization by single intra-testicular injection of CaCl_2 in dogs was used by Samanta (1998), Jana et al (2002) and Chatterjee et al., (2009) and by injection of eugenol by Abshenas et al., (2013). Testicular palpation post injection revealed tenderness in both groups which may be due to

accumulation of fluid inside testicular parenchyma which may also considered the cause of signs of discomfort which appeared on the animals 5-10 minutes post injection, the same result was observed by Jana and Samanta (2007). Signs of scrotal inflammation, erosions and pain were clearly observed in CaCl₂ group during 1st week post injection, this result agreed with Koger (1978) and Canpolat et al., (2006) While Jana and Samanta (2007) reported that the animal showed only signs of mild discomfort which subsided immediately post injection with normal animal gait. Because clove oil is a natural substance and has an analgesic and anti-inflammatory effects (Daniel et al., 2009 and Hosseini et al., 2011), pain and inflammation not observed in clove oil group. Intra-testicular injection of CaCl₂ resulted in replacement of the normal testicular parenchyma with fibrous tissue, complete derangement of the seminiferous tubular architecture with necrosis of the germinal epithelium and replacement of the tubular and interstitial elements with fibrous and hyaline tissues. These changes may be due to the necrotizing properties of CaCl₂ (McGinnis et al., 1999 and Jana and Samanta, 2007). Atrophy and degeneration of the seminiferous tubules with loss of their normal architectures were observed post clove oil injection. Moreover, there were disintegration and washing out of most of their germ cell. Higher concentration of clove oil acts as a pro-oxidant causing increased generation of tissue-damaging free radicals (Asha et al., 2001). It has been also reported to possess antigenotoxic activity (Abraham, 2001). Significant decrease in testosterone was recorded in both groups, this result agreed with Jana and Samanta (2007) and Abshenas et al., (2013). Calcium chloride generating large amount of free radicals or their products in the testicular tissue which results in low level of testosterone (Chainy et al., 1997). Testosterone is a prime regulator for maintenance of structural morphology and normal physiology of seminiferous tubules (Jegou and Sharpe, 1993), so its low concentration resulted in significant fibrosis in testicular tissue and germ cell degeneration which observed clearly in both groups. Any type of stress resulted in an increase of cortisol secretion in dogs (Guyton and Hall, 1996). Cortisol is established as an indicator of stress (Cohen et al., 1990). In this study cortisol level increased significantly during 1st week post CaCl₂ injection, on the other hand Jana and Samanta (2007) stated that chemosterilization with CaCl₂ didn't associated with

any chronic stress. No alteration of cortisol level was observed post clove oil injection; the same result was recorded by Abshenas et al., (2013).

5- CONCLUSION

Chemical sterilization of dogs was achieved successfully after single bilateral intra-testicular injection of both calcium chloride or clove oil; however clove oil proved to be advantageous than calcium chloride as it didn't induce pain and irritation to the dogs.

The authors express gratitude and appreciation to *Dr. Asmaa Fahmy*, lecturer of pathology, faculty of veterinary medicine, Alexandria University, for her help in completion of the part of histopathology.

6- REFERENCES:

- Abraham, S.K. 2001. Anti-genotoxicity of trans-anethole and eugenol in mice. *Food Chem. Toxicol.* 39: 493-498.
- Abshenas, J., Molaei, M.M., Derakhshfar, A., Ghalekhani, N. 2013. Chemical sterilization by intra-testicular injection of *Eugenia caryophyllata* essential oil in dog: A histopathological study. *IJVS.* 8(2): 9-15.
- Asha, M.K., Prashanth, D., Murali, B., Padmaja, R., Amit, A. 2001. Anthelmintic activity of essential oil of *Ocimum sanctum* and eugenol. *Fitoterapia*; 72: 669-670.
- Baba, M. A., Fazili, M.R., Ather, H., Mir, M.S., Moulvi, B.A., Khan, I. 2012. Pinhole castration technique: An alternative to orchiectomy in stray dogs. *Anim. Reprod. Sci.* 137 (1): 113-118.
- Canpolat, I., Gur, S., Gunay, C., Bulut, S., Eroksuz, H. 2006. An evaluation of the outcome of bull castration by intra-testicular injection of ethanol and calcium chloride. *Revue Med. Vet.* 157: 420-425.
- Chainy, G.B.N., Smantary, S., Samanta, L. 1997. Testosterone induced changes in testicular antioxidant system. *Andrologia* 29: 343-50.
- Chatterjee K, Ali, K.M., De, D., Mallick, C., Ghosh, D. 2009. Induction of Chemosterilization by Single Intratesticular Calcium Chloride Injection in Stray Dogs. *Res. J. Anim. Vet. Sci.* 4: 22-29.
- Cohen, R., King, B., Thomas, L., Janzen, E.D. 1990. Efficacy and stress of chemical versus surgical castration of cattle. *Canadian J. Anim.Sci.* 70: 1063-1072.
- Daniel, A.N., Sartoretto, S.M., Schmidt G, Caparroz-Assef, S.M., Bersani-Amado, C.A., Cuman, R.K.N. 2009. Anti-inflammatory and antinociceptive activities A of eugenol essential oil in experimental animal models. *Revista Brasileira de Farmacognosia*; 19:212- 217.
- Dube, D., Assaf, A., Pelletier, G.1987. Morphological study of the effect of an GnRH agonist on the canine testis after 4 months of treatment and recovery. *Acta Endocrinol. (Copenh)*; 116: 413-417.

- Guyton, A.C., Hall, J.E. 1996. The adrenocortical hormones. In: Guyton A.C., Hall, J.E., editors. Text book of medical physiology. New York: W.B. Saunders Company; P. 963-964.
- Ho, Y.C., Huang, F.M., Chang Y.C. 2006. Mechanisms of cytotoxicity of eugenol in human osteoblastic cells in vitro. *Int.endod. J.* 39:389-393.
- Hosseini, M., Asi, M. K., Rakhshandeh, H. 2011. Analgesic effect of clove oil in mice. *Avicenna J. Phytomed*; 1(1): 1-6.
- Jaganathan, S.K., Supriyanto, E. 2012. Antiproliferative and molecular mechanism of eugenol-induced apoptosis in cancer cells. *Molecules* 17: 6290-6304.
- Jana, K., Samanta, P. 2007. Sterilization of male stray dogs with a single intra-testicular injection of calcium chloride: a dose dependent study. *Contraception* 75: 390-400.
- Jana,K., Samanta, P.,Ghosh, D. 2002. Dose dependent response to an intra-testicular injection of calcium chloride for induction of chemosterilization in adult albino rats. *Vet. Res. Comun.*; 26:651-673.
- Jegou,B., Sharpe, R.M. 1993. Paracrine mechanism in testicular control. In: Dekrester D, editor. *Molecular biology of male reproduction*. London: Academic Press. p: 271-95
- Koger, L. 1978. Calcium chloride castration. *Modern Vet. Prac.* 59:119-121.
- Leoci, R., Aiudi, G., Silvestre, F., Lissner, E., Lacalandra, G. 2014. Alcohol diluent provides the optimal formulation for calcium chloride non-surgical sterilization in dogs. *Acta Vet.Scand.*56:62.
- McGinnis, K.M., Wangi, K.K., Genegy, M.E. 1999. Alteration of extra-cellular calcium elicits selective modes of cell death and protease activation in SH-SY5Y human neuroblastoma cells. *J. Neurochem.*; 72: 1853-1863
- Oliveira, E., Moura, M.R., Silva, J.r. VA, Peixoto, C.A., Saraiva, K.L., de SA, M.J. et al. 2007. Intratesticular injection of a zinc-based solution as a contraceptive for dogs. *Theriogenol.*68: 137-145.
- Robertson, S.A.2008. A review of feral cat control. *Journal of Feline Medicine and Surgery*;10: 366-375.
- Samanta,P.K. 1998. Chemosterilization of stray dogs. *Ind. J. Anim. Health*; 37: 61-62.
- SAS, 2006. *Statistical Analysis System*. SAS Carry Incorporation.
- Soto, F., Viana, W., Sousa, A., Pinheiro, S., Mucciolo, G., Hosomi, F. et al. 2007. Evaluation of zinc gluconate, either associated or not to dimethyl sulfoxide, as contraceptive method for male dogs. *J. Anim. Reprod.* 4:119-124.
- Thompson, D., Constantin-Teodosiu D., Egestad, B.r., et al 1990. Formation of glutathione conjugates during oxidation of eugenol by microsomal fractions of rat liver and lung. *Bioch. Pharmacol.* 39:1587-1595.
- Wiebe, J.P., Barr, K.J. 1984. The control of male fertility by 1,2,3- trihydroxypropan (THP; glycerol): rapid arrest of spermatogenesis without altering libido, accessory organs, gonadal steroidogenesis and serum testosterone. LH and FSH. *Contraception*; 29: 291–302.