

DOI: 10.5455/medarh.2012.66.s27-s29

Med Arh. 2012 Jun; 66(3, suppl 1): 27-29

Received: April 10th 2012

Accepted: May 25th 2012

CONFLICT OF INTEREST: NONE DECLARED

ORIGINAL PAPER

Spermiogram Part of Population with the Manifest Orchitis During an Ongoing Epidemic of Mumps

Belma Gazibera, Refet Gojak, Alija Drnda, Akif Osmic, Nermin Mostarac, Ilhama Jusufi-Huric, Planinka Muratovic
Clinic for the Infectious Diseases, Clinical center of University of Sarajevo, Sarajevo, Bosnia and Herzegovina

Introduction: Incidence mumps infection has declined since the introduction of the inevitable MRP vaccination during the stage of childhood. In Bosnia and Herzegovina (BIH), from a period of February 2011 until today, there is an evident inclination of the recorded cases of the mumps infection. Orchitis usually occurs in between 3 to 10 days after the parotitis and is found with the post-puberty population. **Aim:** The aim of the study is to confirm the changes that occur during an early stage of the spermiogram and hormonal status, and after treated mumps orchitis, the patients treated in the Clinic for the Infectious Diseases. **Patients and Methods:** Retrospectively, the analysis of 54 historical diseases was undertaken. During the research stage, the patients after being discharged have made an inquiry to our clinical consultancy units with final results of the spermiogram and hormone-FSH, LH and testosterone. The data analysis was processed with the SPSS program for Windows. **Results:** the average length of the hospitalization period was in between 8 (medium) days, and average age $M(\text{mean}) = 21,9 \pm 5,4$ years. The spermiogram of the treated patients was undertaken one month after the acute phase of the disease and has shown the following results: azoospermia with 14 patients (25,9%), oligospermia with 30 patients (55,6%) and normospermia with 10 patients (18,5%). During the hormonal status with 11 patients (20,4%), the results have shown the inclination of the value in FSH hormones, with 11 patients (20,4%), have shown the lesser value of the testosterons. **Conclusion:** The current study suggests that post-orchitis atrophy is expected within a period of 2-3 months after the infection, and thus, the monitoring on the patients' treatment would continue. The male infertility as a result of mumps orchitis is controversial and continues to be the thematic issue as well as the effect of orchitis on testicular endocrine function. **Key words:** epidemic, mumps infection, spermiogram, orchitis.

Corresponding author: Belma Gazibera, MD. Clinic for Infectious Diseases. Clinical center of Sarajevo University. 71000 Sarajevo. Bolnicka 25. Tel.+387 33 297 253.E-mail: gazibera.belma@gmail.com.

1. INTRODUCTION

The CDC empirically defines mumps as the acute onset of unilateral or bilateral tender, self-limited swelling of the parotid or other salivary glands

longer than 2 days without another apparent cause (1). The mumps virus belongs to the family Paramyxoviridae, spread by airborne droplets and the incubation period is 14-21 days, with

an infectious period from two days before onset of parotitis to 9 days afterwards (2, 3, 4). Since the introduction of the measles-mumps-rubella (MMR) vaccine in 1968 there has been a 99% reduction in the incidence of the virus in the USA (5). Infection results in lifelong immunity. After adolescence, mumps can affect the gonads of both man and women (6). Mumps orchitis is a major complication of a general infection with the mumps virus. In 20 to 25% of men it can involve the testicles (orchitis), unilateral or bilateral. Orchitis typically appears 3-10 days after the onset of parotitis, but it may occur in the absence of parotid involvement. In clinical suspicion (painful swelling of the testicle), history of parotitis and evidence of IgM antibodies in serum provide the diagnosis (5, 7). Infertility in male patients resulting from mumps orchitis is a controversial, as there is conflicting evidence on the endocrine function of the testes (5). The therapy of mumps orchitis is not standardised. The use of systemic α -2b interferon to prevent testicular atrophy has been suggested in several studies. This therapy has demonstrated a superior outcome in terms of men sperm count and percentage normal morphology (8). On the other hand, testicular biopsy after interferon therapy has revealed testicu-

lar atrophy in 38% of man (9).

2. THE AIM OF WORK

The aim of the study is to make a review of relevant clinical and laboratory monitoring of patients who were treated for acute mumps orchitis, to confirm the changes that occur during an early stage of the spermiogram and hormonal status, and after treated mumps orchitis in the patients treated in the Clinic for the Infectious Diseases.

3. PATIENTS AND METHODS

The data analysis was processed with the SPSS program for Windows. Retrospectively, the analysis of 54 historical undertaken. During the research stage, the patients after being discharged have made an inquiry to our clinical consultancy units with final results of the spermiogram and hormone Follicle-stimulating hormone (FSH), Luteinizing hormone (LH) and testosterone.

For the study we used two sets of data. The first group of data from the history of the disease: age, involvement of one or both testicles, length of hospitalization, laboratory tests (C-reactive protein, amylaza in serum and urine), the use of broad spectrum antibiotics and corticosteroid therapy. The second group of data was used from the hospital information system. Patients came to the clinic 1 month after discharge from the findings of the analysis Spermiogram and androgen hormones FSH, LH and testosterone.

4. RESULTS

The average length (median) hospital patients was 8 days (between 6 and 10 days). The shortest hospitalization was 4 and the longest 18 days. The average age of M (mean) 21.9 ± 5.4 years (Graph 1).

The differences of mean values of CRP (median) among subjects categorized according to the findings Spermiogram not statistically significant $p = 0.209$. CRP levels are elevated in all categories according to their values and we can not predict the final result of Spermiogram. Unilateral orchitis had 39 patients. Of these 5 patients (12%) has azospermia at the first control, 27 (69.2%) oligospermia and 7 (17.9%) nor-

			SPERMIOGRAM			
			azosper- imija	oligo- spermia	normo- spermia	total
ORCHITIS	UNI	Count	5	27	7	39
		% within ORHITIS	12.8%	69.2%	17.9%	100.0%
	BILL	Count	9	3	3	15
		% within ORHITIS	60,0%	20,0%	20,0%	100,0%
Total	Count		14	30	10	54
	% within ORHITIS		25.9%	55.6%	18.5%	100.0%

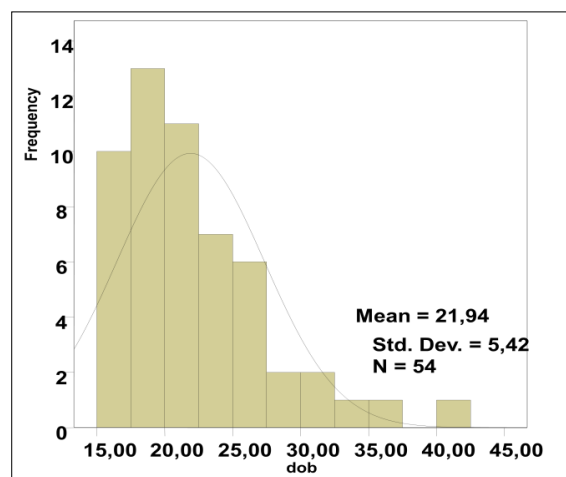
Table 1. The ratio of orchitis in patients included in our study

	Spearman's rho	Orchitis uni/bill	Antibiotik	FSH	LH	TESTOSTERON
SPERMIO-GRAM	Correlation Coefficient	-0.319(*)	0.086	-0.585(**)	-0.216	0.296(*)
	p	0.019	0.535	0.0005	0.117	0.030
	N	54	54	54	54	54

Table 2. Correlation of orchitis with spermiogram at patients in our study * Correlation is significant at the 0.05 level (2-tailed). ** Correlation is significant at the 0.01 level (2-tailed).

mospermia. Bilateral orchitis had 15 patients of which nine of them (60%) has azospermia, 3 (20%) oligospermia and 3 (20%) normospermia (Table 1).

Mann Whitney test confirmed that the average hospital stay (median) of patients with unilateral and bilateral orchitis statistically significant, $p=0.004$; Patients with unilateral orchitis were hospitalized 7 (6-10) days, bilateral 11 (8-14) days. Differences in the mean length of hospital stay (median) among subjects categorized according to the findings Spermiogram not statistically significant, but are indicative $p=0.055$. The longest suffered by those with azospermia Med=10 (7.7 to 13.2), followed by respondents with normospermia Med is 8.5 (6.5 to 11.2), and finally patients with oligospermia Med = 7 (6–9) days. Spermiogram correlated with the side orchitis $\rho = -0.319$, $p=0.019$. The correlation is negative and mild. If you extend the single-sided orchitis greater the chance for oligo-azospermia. Spermiogram correlated with FSH $\rho = -0.585$, $p<0.005$. Correlation is a medium and negative. Azoo or oligospermija lead to increased FSH values. Spermiogram correlated with testosterone $\rho = 0.296$, $p=0.03$. Correlation is a mild and positive. Patients with azoo or oligospermia have less testosterone values.



Graph 1. Age distribution of the hospitalized patients with MUMPS (the frequency and age)

5. DISCUSSION

Between February 2011. until today we have an evident increase in reported cases of mumps infection and mumps, besides, a large number of patients with other manifestations (orchitis and meningitis), which indicates that there is a serious public health problem and epidemiological. We did not have adequate access to the vaccine records of respondents considering it was mostly about the war and post-war period when the subjects were not vaccinated. The average age (M – mean = 21.9 ± 5.4) patients affected by the epidemic corresponds to the expected group that is most at risk for complications of mumps infection reporting. The data correspond to other published studies (3, 10). In the material analyzed, 27.7% of respondents had bilateral orchitis, that the results have a

greater chance of finding Spermiogram disorder, hormones and testicular atrophy. We have presented data related to the initial Spermiogram and hormones are given a short period of follow-up, still do not know in which percentage will be expressed in testicular atrophy. Therefore, an essential and will be a further period of monitoring of these patients. Literally the testicular atrophy after acute orchitis described in 30-50% of cases. A month to 6 months after the acute phase of disease develops atrophy and degree of atrophy is not necessarily proportional to the severity of acute orchitis. Unilateral atrophy occurs in about one third of patients and bilateral in the tenth (11, 12, 13). We found significant differences in serum hormones, increased FSH and decreased testosterone values. FSH is generally inversely correlated with spermatogenesis and if the germinal epithelium is damaged, the FSH levels rise. Indirectly, these findings may be a significant predictor of male infertility. According to the Spanish recent study, the results point to a change in spermiogram but the hormonal status of normal or even low FSH along with reduced levels of testosterone and inhibin B was used in the treatment of alpha-interferon in contrast to our treatment protocol (14).

6. CONCLUSION

During the follow-up period a high incidence of sperm disturbance was found. Mumps viral infection of the germ cells may result a serious risk for the fertility and general health of the individual, with special emphasis on mental health. The current study suggests that post-orchitis atrophy is expected within a period of 3-6 months after the infection, and thus, the monitoring on the patients treatment would continue. The male infertility as a result of mumps orchitis is controversial and continues to be the thematic issue as well as the effect of orchitis on testicular endocrine function.

REFERENCES

1. Center for Disease Control and Prevention (CDC) Mumps Epidemic- United Kingdom, 2004-2005. 2006, Feb 24: 55(7): 173-175.
2. Philip J. et al. Mumps orchitis in the non-immune postpubertal male: a resurgent threat to male fertility? 2006; 97(1): 138-141
3. Douglas G. Mackenzie. Mumps in a boarding school: description of an outbreak and control measures. *Br J Gen Pract.* 2006 July 1;56(528): 526-529.
4. Dejucq N, Jegou B. Viruses in the Mammalian Male Genital Tract and Their Effects on the Reproductive System. *Microbiol Mol Biol Rev.* 2001 June; 65(2): 208-231.
5. Davis NF, McGuire BB. et al. The increasing incidence of mumps orchitis: a comprehensive review. 2010 *BJU INTERNATIONAL* /105: 1060-1065 /
6. Shanley JD. The resurgence of mumps in young adults and adolescents. *Cleveland Clinic Journal of Medicine.* 2007; 74(1): 42-46.
7. Ludvig M. Diagnosis and therapy of acute prostatitis, epididimitis and orchitis. 2008 Blackwell Publishing Ltd. *Andrologia.* 2008; 40: 76-78.
8. Ku JH, Kim YH et al. The preventive effect of systemic treatment with interferon-alpha2B for infertility from mumps orchitis. *BJU Int.* 1999; 84: 839-842.
9. Scholz M. et al. Mumpsorchitis im Jugend-und Erwachsenenalter. *Dt. Arztlbl.* 1996; 93: 2087-2090.
10. Pugh RN, Akinosi B, Pooransingh S. et al. An outbreak of mumps in the metropolitan area of Walsall, UK. *Int J Infect Dis.* 2002; 6: 283-287.
11. Beard CM. et al. The incidence and outcome of mumps orchitis in Rochester, Minesota, 1935-1974. *Mayo Clin Proc.* 1977; 52: 3-7.
12. James E. Griffin, Jean D. Willson. *Oboljenja testisa. U: Harisonova načela interne medicine. Berdfin and Romanov,* 2004: 2143-2150
13. Tsvetkov D. Spermatological disorders in patients with postmumps orchitis. *Akush Ginekol (Sofia).* 1990; 29(6): 46-49.
14. Ternavasio-de la Vega HG et al. Mumps orchitis in the post-vaccine era (1967-2009): a single-center series of 67 patients and review of clinical outcome and trendt. *Medicine (Baltimore).* 2010 Mar; 89(2): 96-116.